

# Original Article

## Tuberculous uveitis at a referral center in southeastern Brazil\*

Uveíte por tuberculose em um centro de referência no Sudeste do Brasil

Wesley Ribeiro Campos<sup>1</sup>, Juliana Fulgêncio Henriques<sup>2</sup>, Afrânio Lineu Kritski<sup>3</sup>,  
André Curi<sup>4</sup>, Rosita Tomishi Pimentel<sup>5</sup>, Silvana Spindola de Miranda<sup>6</sup>

### Abstract

**Objective:** To describe the occurrence of tuberculous uveitis (TBU) at a referral center in the state of Minas Gerais, Brazil. **Methods:** A total of 16 consecutive patients ( $\geq 15$  years of age) who underwent diagnostic evaluation of uveitis between January of 2001 and July of 2004 at the Minas Gerais State Referral Center were selected for study. Demographic and clinical data, as well as data related to screening for toxoplasmosis, syphilis, and rheumatologic diseases, together with the results of tuberculin skin testing and HIV testing, were collected. **Results:** Of the 16 patients evaluated, 11 (69%) were found to have TBU. A history of contact with pulmonary tuberculosis was reported by 8 (72%) of the 11 patients with TBU and by 1 (20%) of the 5 with non-TBU. Although the odds ratio for this association was 10.67 (95% CI: 0.59-398.66), the  $p$  value was borderline significant ( $p = 0.078$ ). There was no difference between the patients with TBU and those with non-TBU in terms of the status of ocular inflammation or the tuberculin skin testing results. All of the patients were HIV negative and were monitored for two years. **Conclusion:** In this study, a history of contact with pulmonary tuberculosis proved to be useful in diagnosing TBU.

**Keywords:** Tuberculosis; Uveitis; Diagnosis; Brazil.

### Resumo

**Objetivo:** Descrever a ocorrência de uveíte por tuberculose (UTB) em um centro de referência em Minas Gerais, Brasil. **Métodos:** Um total de 16 pacientes (idade  $\geq 15$  anos) atendidos consecutivamente de janeiro de 2001 a julho de 2004 no Centro de Referência de Uveíte do Estado de Minas Gerais para avaliação diagnóstica de uveíte foi selecionado para este estudo. Foram coletados dados demográficos e clínicos, assim como dados sobre avaliação para toxoplasmose, sífilis e doenças reumatológicas, teste tuberculínico e sorologia anti-HIV. **Resultados:** Dos 16 pacientes, 11 (69%) tinham UTB. História prévia de contato com tuberculose pulmonar foi relatada por 72% (8/11) dos pacientes do grupo com UTB e por 20% (1/5) dos pacientes do grupo sem UTB. Embora a razão de chances para essa associação tenha sido de 10,67 (IC95%: 0,59-398,66), o valor de  $p$  apresentou significância limítrofe (0,078). Não houve diferença quanto ao quadro ocular inflamatório e ao resultado do teste tuberculínico entre os pacientes com UTB e os sem UTB. Todos os pacientes tinham sorologia negativa para o HIV e foram acompanhados por 2 anos. **Conclusão:** Neste estudo, a história prévia de contato com tuberculose pulmonar foi de grande ajuda para o diagnóstico da UTB.

**Descritores:** Tuberculose; Uveíte; Diagnóstico; Brasil.

\* Study carried out at the Federal University of Minas Gerais School of Medicine and *Hospital das Clínicas*, Belo Horizonte, Brazil.

1. Adjunct Professor of Ophthalmology. Federal University of Minas Gerais School of Medicine, Belo Horizonte, Brazil.

2. Resident Physician. Felício Rocho Hospital, Belo Horizonte, Brazil.

3. Adjunct Professor of Clinical Medicine/Pulmonology. Federal University of Rio de Janeiro School of Medicine, Rio de Janeiro, Brazil.

4. Physician Researcher. *Fundação Oswaldo Cruz* – FIOCRUZ, Oswaldo Cruz Foundation – Rio de Janeiro, Brazil.

5. Resident Physician. Federal University of Minas Gerais School of Medicine, Belo Horizonte, Brazil.

6. Associate Professor I of Clinical Medicine/Pulmonology. Federal University of Minas Gerais School of Medicine, Belo Horizonte, Brazil.

Correspondence to: Wesley Ribeiro Campos. Av. Alfredo Balena, 190, Santa Efigênia, CEP 30130-100, Belo Horizonte, MG, Brasil.

Tel 55 31 3248-9599. E-mail: spindola@medicina.ufmg.br

Submitted: 31 January 2007. Accepted, after review, 11 June 2007.

## Introduction

Tuberculosis (TB) typically involves the lungs. The pulmonary forms account for 85% of all cases, whereas the extrapulmonary forms account for only 15%. In Brazil, pleural and lymph node TB are the most common presentations, followed by miliary, meningeal, genitourinary, osseous, and ocular TB.<sup>(1-3)</sup>

Although ocular TB can affect any of the tissues of the eye, it most often affects the uvea.<sup>(4)</sup> In most studies, patients with ocular TB do not present respiratory symptoms, radiological signs, or positive bacteriology.<sup>(2,5,6)</sup> Primary ocular infection involving the conjunctiva and cornea has been described, and intraocular TB has been classified as being secondary to infection at a distant primary site.<sup>(7)</sup>

In 1941, Guyton & Woods suggested that 78% of all cases of uveitis were related to TB.<sup>(8)</sup> In 1954, Woods found a significantly lower proportion.<sup>(9)</sup> Of the cases of uveitis evaluated by the author, only 14% were cases of tuberculous uveitis (TBU). This discrepancy might be attributed to increased stringency in the diagnostic criteria and improvements in serologic testing, as well as to the greater number of alternative etiologies, such as sarcoidosis and toxoplasmosis, which were not often considered at the time of the Guyton & Woods study.

A presumptive diagnosis of TBU is made empirically, through successful treatment with anti-TB drugs,<sup>(1,10)</sup> as proposed in the guidelines established by the Brazilian National Ministry of Health and by others.<sup>(1,4,7,11)</sup> However, there are scarce data on its usefulness in developing countries with a high prevalence of TB infection.

The goal of this study was to describe the clinical and epidemiological aspects of TBU at a referral center in the city of Belo Horizonte, located in the state of Minas Gerais, Brazil.

## Methods

From January of 2001 to July of 2004, a total of 16 patients evaluated for ocular TB were enrolled in this study, according to sample availability, after giving written informed consent. The content of the consent form was approved by the local ethics committee. The patients, all of whom presented ocular alterations, were referred from various health facilities (infectious disease clinics, general practice clinics, basic health clinics, other ophthalmology

centers, and hospitals). The patients were consecutively treated at the Uveitis Outpatient Clinic of the Department of Ophthalmology of the Federal University of Minas Gerais University Hospital. Demographic and clinical data, as well as data regarding screening for toxoplasmosis, syphilis, and rheumatologic diseases, together with the results of tuberculin skin testing (TST) and HIV testing, were collected for all patients, except for 1 patient who was a minor (15 years of age). These data were recorded on individual data collection forms and entered into a computer database.

In the statistical analysis, the Student's t-test was used for continuous variables of normal distribution, whereas the chi-square test or Fisher's exact test, as appropriate, were used in the analysis of categorical variables. Values of  $p \leq 0.05$  were considered statistically significant.

The following criteria were defined for the diagnosis of TBU: ruling out syphilis (negative serology), toxoplasmosis - negative IgM serology and absence of typical retinochoroiditis (scarred patches and active satellite lesions) - and sarcoidosis; negative serology for and no clinical signs of rheumatologic diseases; TST induration  $\geq 10$  mm; and improvement after 6 months of anti-TB treatment.<sup>(1,10,12,13)</sup>

Uveitis was classified as non-TBU when, despite the criteria mentioned above, any of the following were observed: worsening or no improvement during treatment; resurgence of disease activity after the end of treatment; and discovery of a new disease. All patients were evaluated monthly until having completed 24 months of follow-up evaluation.

Patients with respiratory symptoms were submitted to sputum smear microscopy, mycobacteria culture, and chest X-ray, all tests being performed in the Respiratory Medicine Department.

A standardized questionnaire was administered in order to evaluate the presence of TB risk factors. The purified protein derivative (PPD) RT-23 (State Serum Institute, Copenhagen, Denmark), which corresponds to two (standard) tuberculin units (2 TU) of *Mycobacterium tuberculosis* (Mtb), was used. The TST was performed and read by trained staff. Induration at the site of the TST was measured 48 to 72 h later using the palpation method.<sup>(1,13)</sup>

## Results

Of the 16 patients included in the study, 11 (69%) were diagnosed with TBU. In the group with TBU, the mean age was 45.5 years (range, 23-68 years), compared with 29.8 years (range, 15-51 years) in the group with non-TBU ( $p = 0.074$ ). All patients were HIV-negative.

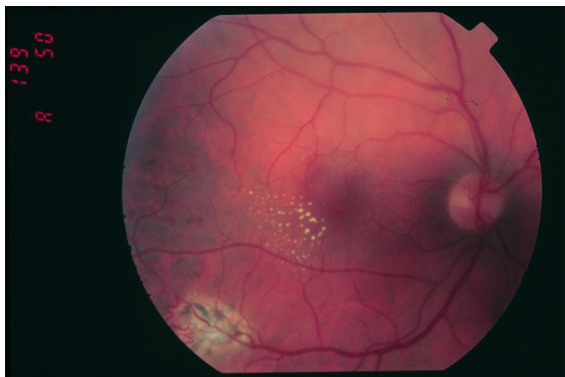
No significant differences were found between the TBU group and the non-TBU group in terms of sociodemographic or clinical variables.

A history of contact with pulmonary TB was reported by 8 (72%) of the 11 patients with TBU and by 1 (20%) of the 5 with non-TBU. Although the odds ratio for this association was 10.67 (95% CI: 0.59-398.66), the  $p$  value was borderline significant ( $p = 0.078$ ).

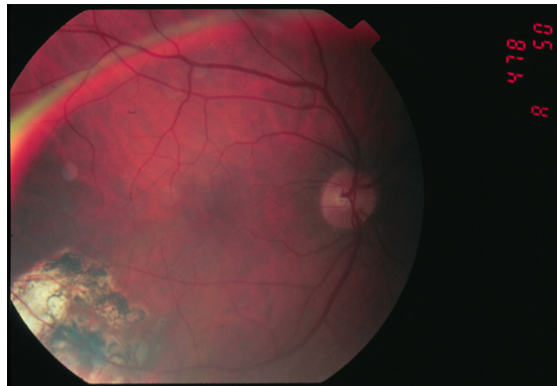
Of the 11 patients with a final diagnosis of TBU, 5 presented anterior uveitis/scleritis, and 6 presented posterior involvement (Figures 1 and 2). Nine cases were unilateral, and one was bilateral. In one case, the fellow eye was atrophic (Table 1). The average TST induration in patients with TBU was  $16.8 \pm 2.86$  mm. In 2 patients, there was concomitance with another form of TB (renal TB and pulmonary TB, respectively) with bacteriological confirmation, that is, positive culture for *Mtb*. The patient with pulmonary TB did not undergo TST or have a history of contact with pulmonary TB. During the follow-up period, there was no recurrence of the uveitis.

Of the 5 patients with a final diagnosis of non-TBU, 3 presented posterior uveitis (idiopathic

neuroretinitis, idiopathic choroiditis, and toxoplasmic retinochoroiditis) and 2 presented diffuse uveitis (Vogt-Koyanagi-Harada syndrome and Wegener's granulomatosis, respectively), the disease being unilateral in 3 cases and bilateral in 2 (Table 2). The average TST induration was  $18 \pm 2.35$  mm. Of the same 5 patients, 3 had received anti-TB drugs for up to 3 months, without any clinical improvement, and 2 had completed the treatment but had presented reactivation of the uveitis during the follow-up period. In the case diagnosed as toxoplasmic retinochoroiditis, the diagnosis was delayed, since the patient had initially been treated for toxoplasmosis, with no improvement, was subsequently treated for TBU, still with no improvement, and was finally treated successfully for toxoplasmosis (healed lesion). A history of contact with pulmonary TB was reported only by the patient presenting clinical features consistent with Vogt-Koyanagi-Harada syndrome, who, although presenting signs of late manifestations during re-examination, healed satisfactorily. The patient diagnosed with Wegener's granulomatosis underwent enucleation of one eye due to subsequent scleritis that caused retinal detachment and a painful blind eye (confirmed through histopathological examination). That patient responded well to pulse therapy and systemic corticosteroids. The 2 remaining non-TBU patients (those diagnosed with idiopathic neuroretinitis and idiopathic choroiditis, respectively) presented intermittent disease and were treated with oral corticosteroids during flare-ups.



**Figure 1** - Chorioretinal lesion associated with retinal vasculitis and microangiopathy. Note incomplete macular star (right eye).



**Figure 2** - Complete resolution of the chorioretinal lesions following tuberculosis treatment.

**Table 1** - Patients with tuberculous uveitis.

Patient	Age (years)	Gender	Eye (s)	Ocular lesion	TST induration	Chest X-ray	History of contact with pulmonary TB	Other forms of TB
1	41	M	Both	Vasculitis	13 mm	N	Yes	No
2	32	M	Both	Serous retinal detachment	19 mm	N	No	No
3	23	F	Left	Kerato-sclero-uveitis	12 mm	N	No	No
4	56	F	Right	Iridocyclitis	17 mm	A	Yes	Yes (renal)
5	65	F	Right	Kerato-episcleritis	18 mm	N	Yes	No
6	68	F	Left	Tractional retinal detachment	20 mm	A	Yes	No
7	29	M	Right	Vasculitis, chorioretinitis, vitreous hemorrhage, tractional retinal detachment	20 mm	N	Yes	No
8	32	M	Left	Tractional retinal detachment, chorioretinitis	18 mm	N	Yes	No
9	54	F	Left	Optic neuritis/choroiditis	14 mm	A	Yes	No
10	58	F	Right	Granulomatous iridocyclitis	17 mm	N	Yes	No
11	43	F	Right	Scleritis	NA	A	No	Yes (pulmonary)

N: normal; A: abnormal; TST: tuberculin skin testing; and NA: not applicable (positive smear).

## Discussion

Over the last two decades, due to deficiencies in the public health system, as well as to poverty and the AIDS epidemic, the incidence of pulmonary and extrapulmonary TB has increased in Brazil.<sup>(3)</sup> In order to control TB in the city of Belo Horizonte, a referral center for ocular TB, the Uveitis Outpatient Clinic, was established through an agreement between the University Hospital Departments of Pulmonology and Ophthalmology. The increasing number of cases of ocular TB in our department in the last four years may be a reflection of this interaction.

According to various studies, TBU presents lesions similar to those seen in anterior or posterior uveitis.<sup>(14,15)</sup> In our study, we found no differences between anterior or posterior uveitis. Unilateral

involvement occurred in 82% of the cases, as has been shown in the literature.<sup>(16,17)</sup> Concomitant ocular TB or other forms of TB are uncommon.<sup>(2)</sup> In our study, we found that 18% of the patients presented this combination. There were no lesions suggesting other diseases in the individuals analyzed.

Some authors<sup>(18)</sup> have suggested the use of a TST cut-off point of 15 mm or 20 mm to determine Mtb infection in regions with a low prevalence of TB, in addition to using 5-TU PPD. In our study, we employed a TST cut-off point of 10 mm to determine Mtb infection, as described by many national and international authors who use 2-TU PPD.<sup>(12,13)</sup> However, in order to identify active TB, clinical and epidemiological criteria were used, despite the fact that most of the TST values were  $\geq 15$  mm.

**Table 2** - Patients with non-tuberculous uveitis.

Patient	Age (years)	Gender	Eyes (s)	Ocular lesion	Cause	TST induration	Chest X-ray	Treatment	History of contact with pulmonary TB
1	51	F	Both	Neuroretinitis	Idiopathic	19 mm	N	Stopped	Yes
2	19	F	Right	Chorioretinitis	Toxoplasmosis	20 mm	N	Completed	No
3	32	M	Both	Vasculitis	WG	16 mm	N	Completed	No
4	32	M	Left	Choroiditis	VKHS	20 mm	N	Stopped	No
5	15	F	Left	Choroiditis	Idiopathic	15 mm	N	Completed	No

WG: Wegener's granulomatosis; VKHS: Vogt-Koyanagi-Harada syndrome; TST: tuberculin skin testing; and N: normal.

In the present study, TBU was confirmed in 69% of the cases in which the modified Brazilian National Ministry of Health criteria were adopted (excluding positivity in TST as a marker of TBU). According to those criteria, the diagnosis of ocular TB was confirmed in 11 patients after two years, since they did not present recurrence of the uveitis. If, as proposed by other authors,<sup>(1,10)</sup> we included TST positivity as a criterion for the diagnosis of TBU in a setting with high prevalence of TB infection, 31% of our cases would have been diagnosed as cases of TBU. In another study, a history of contact with pulmonary TB was shown to present a correlation (albeit a weak one) with TBU.<sup>(19)</sup> Using a history of contact with pulmonary TB as an additional diagnostic criterion, 4 of the 5 non-TBU patients evaluated in the present study would not have been subjected to anti-TB treatment.

The difficulties in ruling out other causes of uveitis remain, since there are no lesions that can be considered typical of TBU, as evidenced in the present study. We recommend that information regarding patient history of contact with pulmonary TB be collected as one means of facilitating the diagnosis of TBU.

## Acknowledgments

We wish to thank the Federal University of Minas Gerais and all the patients who participated in this study. We would also like to thank Dr. Daniel Victor Vasconcelos for reviewing the manuscript.

## References

1. Ministério da Saúde. Brasil. Fundação Nacional de Saúde. Centro de Referência Prof. Hélio Fraga. Sociedade Brasileira de Pneumologia e Tisiologia. Controle da tuberculose: Uma proposta de integração ensino-serviço. 5th ed. Rio de Janeiro: FUNASA/CRPHF/SBPT; 2002.
2. Campos WR, Spíndola de Miranda S, Oréfice F. Tuberculose. In: Oréfice F, editor. Uveíte: Clínica e Cirúrgica: Texto & Atlas. 2nd Ed. Rio de Janeiro: Cultura Médica; 2005. p. 509-30.
3. DATASUS [homepage on the Internet]. Brasília: Ministério da Saúde. [updated 2005; cited 2006 Aug 18]. Informações de Saúde. Available from: <http://tabnet.datasus.gov.br>
4. Karim A, Laghmari M, Boutimzine N, Lamarti A, Ibrahimy W, Essakali N, et al. [Choroidal granuloma revealing tuberculosis. A case report][Article in French]. *J Fr Ophthalmol.* 2003;26(6):614-7.
5. Haddon R. An airman with tuberculous uveitis: case study. *Aviat Space Environ Med.* 2000;71(12):1254-5.
6. Sheu SJ, Shyu JS, Chen LM, Chen YY, Chirn SC, Wang JS. Ocular manifestations of tuberculosis. *Ophthalmology.* 2001;108(9):1580-5.
7. Oréfice F, Carvalho A, Pinheiro S. Controvérsias nas uveítes tuberculosas. *Arq Bras Oftalmol.* 1987;50(6):237-45.
8. Guyton JS, Woods AC. Etiology of Uveitis. A clinical study of 562 cases. *Arch Ophthalmol.* 1941;26:983-1018.
9. Woods AC. Pathogenesis and treatment of ocular tuberculosis. *AMA Arch Ophthalmol.* 1954;52(2):174-96.
10. Kritski AL, Conde MB, Souza GR. Tuberculose: do ambulatório à enfermaria. 2nd ed. São Paulo: Atheneu; 2000.
11. Bass JB Jr, Farer LS, Hopewell PC, O'Brien R, Jacobs RF, Ruben F, et al. Treatment of tuberculosis and tuberculosis infection in adults and children. American Thoracic Society and the Centers for Disease Control and Prevention. *Am J Respir Crit Care Med.* 1994;149(5):1359-74.
12. Silva VM, Cunha AJ, Kritski AL. Risco de infecção pelo *Mycobacterium tuberculosis* entre alunos da Faculdade de Medicina da Universidade Federal do Rio de Janeiro. *J Bras Pneumol.* 2004;30(5):459-66.
13. Richeldi L. An update on the diagnosis of tuberculosis infection. *Am J Respir Crit Care Med.* 2006;174(7):736-42.
14. Morimura Y, Okada AA, Kawahara S, Miyamoto Y, Kawai S, Hirakata A, et al. Tuberculin skin testing in uveitis patients and treatment of presumed intraocular tuberculosis in Japan. *Ophthalmology.* 2002;109(5):851-7.
15. Perkins ES, Folk J. Uveitis in London and Iowa. *Ophthalmologica.* 1984;189(1-2):36-40.
16. Helm CJ, Holland GN. Ocular tuberculosis. *Surv Ophthalmol.* 1993;38(3):229-56.
17. Carvalho AZ, Oréfice F. Inquérito tuberculínico: estudo realizado em portadores de uveítes, esclerites e episclerites de causa endógena. *Arq Bras Oftalmol.* 1988;51(2):53-8.
18. Tissot F, Zanetti G, Francioli P, Zellweger JP, Zysset F. Influence of bacille Calmette-Guérin vaccination on size of tuberculin skin test reaction: to what size? *Clin Infect Dis.* 2005;40(2):211-7.
19. Almeida SR, Finamor LP, Muccioli C. Alterações oculares em pacientes com tuberculose. *Arq Bras Oftalmol.* 2006;69(2):177-9.