

Letter to the Editor

Lung transplantation without the use of cardiopulmonary bypass in a patient with Kartagener syndrome

Transplante pulmonar sem circulação extracorpórea em
uma paciente com síndrome de Kartagener

Luziélío Alves Sidney Filho, Tiago Noguchi Machuca, José de Jesus Camargo,
José Carlos Felicetti, Spencer Marcantonio Camargo, Fabíola Adélia Perin,
Letícia Beatriz Sanchez, Sadi Marcelo Schio

To the Editor:

We read with great interest the article by Athanazio et al. addressing the issue of whether the bronchiectasis treatment given to cystic fibrosis patients should be extrapolated to those with bronchiectasis from other causes.⁽¹⁾ Primary ciliary dyskinesia is a rare condition that results in the formation of bronchiectasis, and surgical treatment is invariably indicated. Some of the patients with this condition develop advanced lung disease refractory to clinical treatment and surgical resection, therefore becoming candidates for lung transplantation. When associated with dextrocardia, bronchiectasis, and chronic sinus disease, primary ciliary dyskinesia is designated Kartagener syndrome and is considered a contraindication to lung transplantation in many centers.^(2,3)

Thirteen years ago, we treated a 26-year-old female patient who had Kartagener syndrome and a history of recurrent pneumonia, together with localized bronchiectasis refractory to clinical treatment. Left middle lobectomy and right lingulectomy were indicated. The patient remained asymptomatic for 10 years, at which point the pneumonia recurred because of new foci of bronchiectasis (Figure 1), the patient showing significant lung function impairment requiring continuous oxygen therapy at 7 L/min.

The patient was evaluated for lung transplantation and was included on a waiting list. She had an FEV₁ of 0.52 L (18.6% of predicted) and an FVC of 0.63 L (18.5% of predicted). Her six-minute walk distance was 197 m with desaturation of 19% (SpO₂ having decreased from 94% to 75%). Her pulmonary artery systolic pressure was 32 mmHg, and she presented with 79% perfusion in the right lung.

While on the waiting list, the patient experienced severe deterioration in lung function due to infection with resistant organisms (*Acinetobacter baumannii*), and mechanical ventilation was therefore required. She underwent tracheostomy on the seventh day of mechanical ventilation and was successfully treated with a prolonged course of linezolid. The patient was still in the ICU when a compatible organ became available. She underwent bilateral lung transplantation.

The procedure was performed through bilateral transverse thoracosternotomy (clamshell incision), and, because of the dextrocardia, the superior and inferior vena cava were on the left side (Figure 2). First, lysis of adhesions was performed, followed by dissection of the left pulmonary hilum and pneumonectomy (21% perfusion). There was no hemodynamic instability or desaturation after clamping of the left pulmonary artery, and single-lung ventilation was well tolerated. Therefore, cardiopulmonary bypass (CPB) was not used.

The left bronchus (which was shorter than the right) was sectioned juxta-proximal to the branching to the upper lobe, and pneumonectomy was completed. End-to-end bronchial anastomosis was performed with continuous 4-0 polydioxanone suture, end-to-end arterial anastomosis was performed with continuous 6-0 polypropylene suture, and end-to-end atrial anastomosis was performed with continuous 5-0 polypropylene suture.

After reperfusion, we proceeded similarly for the right side. The pleural cavities were drained with 32F and 36F chest tubes, and surgical time was 330 min.

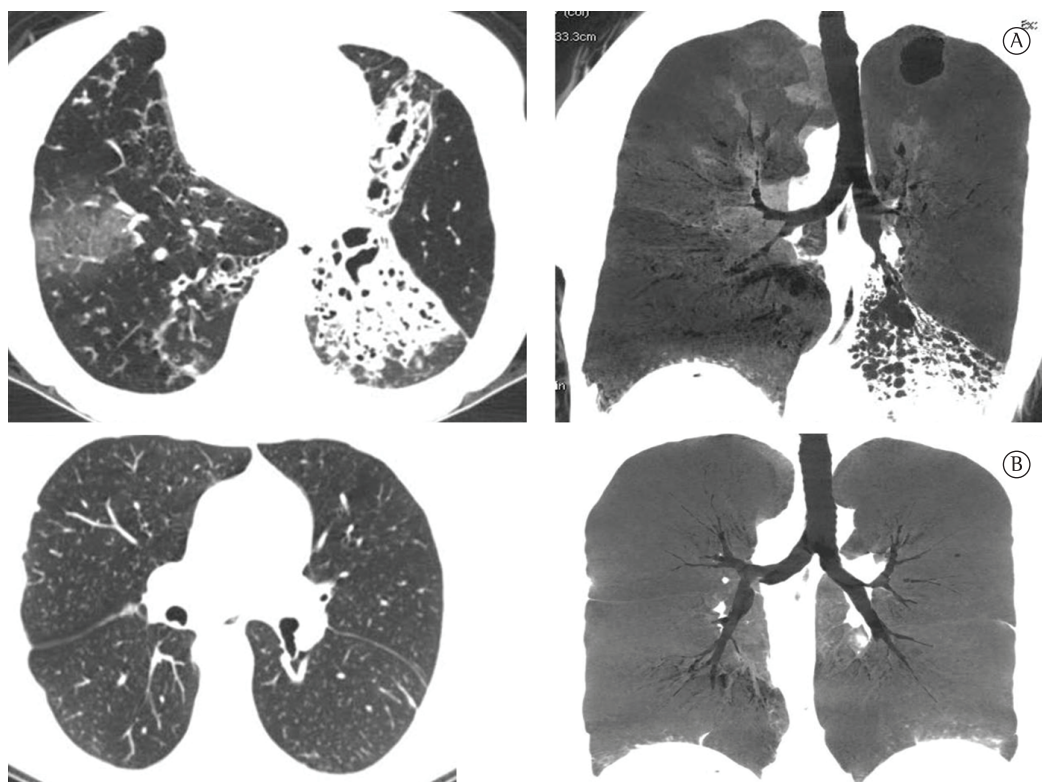


Figure 1 – In A, preoperative chest CT scans showing areas of bronchiectasis. In B, chest CT scans taken two months after transplantation and revealing healthy lungs and no bronchiectasis.

The postoperative period was uneventful. The patient received antibiotic prophylaxis with linezolid and piperacillin-tazobactam until the culture results were known. The tracheostomy tube was removed on postoperative day 2. The patient was discharged from the ICU on postoperative day 15 and was discharged from the hospital on postoperative day 30. The patient had no acute rejection or infection with cytomegalovirus during hospitalization.

At postoperative month 2, the patient had an FEV₁ of 2.05 L (74.3% of predicted) and an FVC of 2.45 L (75.4% of predicted). At postoperative month 6, her FEV₁ was 2.27 L (81% of predicted). At this writing (postoperative month 12), the patient had an FEV₁ of 2.47 L (85% of predicted) and an FVC of 2.37 L (82.4% of predicted).

Lung transplantation is indicated for patients with clinically unmanageable advanced bronchiectasis and significantly impaired lung function. This group includes patients with cystic fibrosis and those with other types of bronchiectasis, although it rarely includes those with Kartagener syndrome. Although the

presence of Kartagener syndrome is considered a contraindication for lung transplantation in some centers, lung transplantation is the procedure of choice, provided that the usual technique is modified.⁽³⁾

In *situs inversus*, lung anatomy is reversed, and finding a donor with *situs inversus* is extremely unlikely. Therefore, techniques were developed for lung transplantation in such cases. It is a challenging procedure, being indicated for patients without cardiac involvement.⁽⁴⁻⁶⁾

Miralles et al. were the first to describe heart-lung transplantation in this situation, proposing the creation of a large single atrium that, through CPB, was anastomosed to the donor atrium.⁽⁵⁾ In 1996, Rábago et al. modified that technique, rotating the cardiac apex in order to restore normal anatomy.⁽⁶⁾ In 2009, Deuse & Reitz anastomosed a portion of the superior vena cava to the donor atrial appendage without the use of vascular prostheses.⁽⁴⁾ In all of the cases described above, there was heart-lung transplantation and use of CPB.

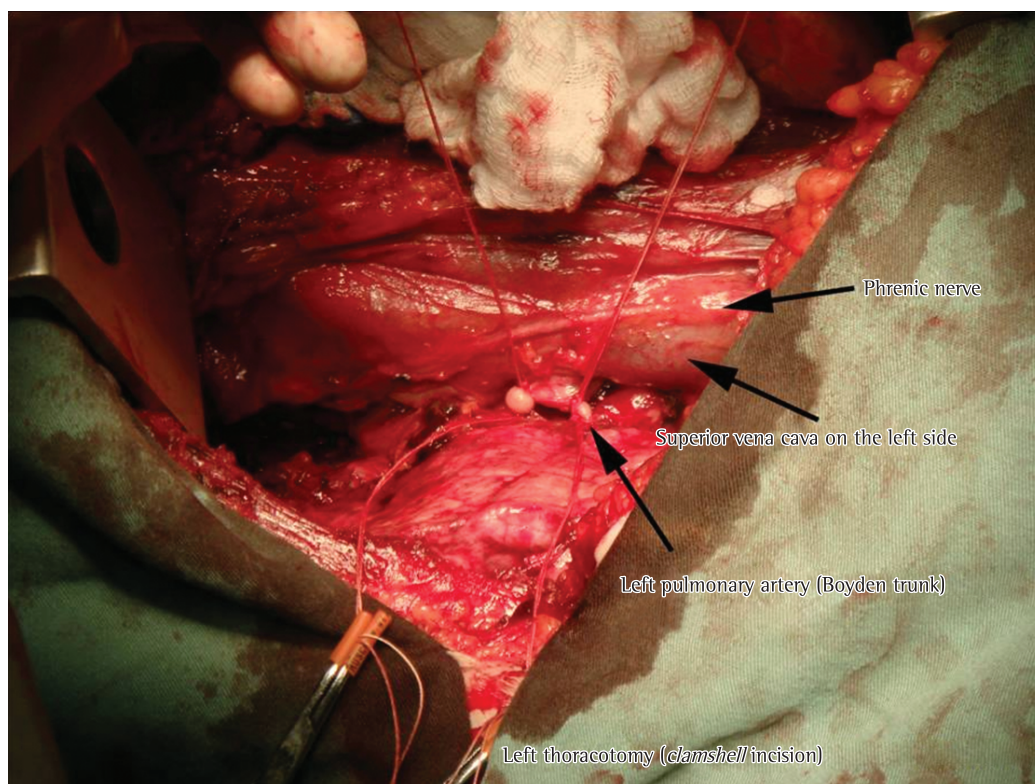


Figure 2 – View of the left hemithorax showing the vena cava on the left side and ligation of the vessels for pneumonectomy.

Patients with *situs inversus* rarely present with cardiac function impairment requiring heart transplantation, and, because of the embolic complications caused by the creation of large atria, alternative techniques were developed for bilateral lung transplantation without heart transplantation. In 1994, Macchiarini et al. reported three cases in which only bilateral lung transplantation was performed.⁽⁷⁾ The technique employed by those authors is similar to the technique that we employed in our patient, except for the use of a median sternotomy rather than a clamshell incision in two of the three patients. Unlike other authors, Macchiarini et al. anastomosed the bronchi rather than the trachea; nevertheless, the three patients were placed on CPB.⁽⁷⁾

In 2000, the procedure was performed without the use of CPB for the first time, having been performed through sequential bilateral thoracotomies in a 15-year-old female patient; a technical modification was needed in order to adjust bronchial size, and ischemia time was 460 min, which is a long period of ischemia.⁽⁸⁾ In the case reported here, the clamshell incision

was used, and surgical time was 330 min, which reduced ischemia time.

Recently, Date et al. performed living donor transplantation for primary ciliary dyskinesia in a 24-year-old female patient on mechanical ventilation, and CPB was used.⁽⁹⁾

Referral centers will inevitably have to face these challenges. Because it is difficult to perform studies that are more comprehensive, cases like the one presented here should be reported in order to add to the experience and discussion. We demonstrated the good results obtained in a high-risk patient (with multidrug-resistant organism colonization and on mechanical ventilation) and reviewed alternative techniques that can be useful in other centers.

Luziélío Alves Sidney Filho
Thoracic Surgeon of the Lung
Transplant Group at the Santa Casa
Hospital Complex in Porto Alegre,
Porto Alegre, Brazil

Tiago Noguchi Machuca
Thoracic Surgeon of the Lung
Transplant Group at the Santa Casa
Hospital Complex in Porto Alegre,
Porto Alegre, Brazil
Fellow in Thoracic Surgery,
Toronto General Hospital,
Toronto, ON, Canada

José de Jesus Camargo
Head of the Department of Thoracic
Surgery and Coordinator for the Lung
Transplant Group at the Santa Casa
Hospital Complex in Porto Alegre,
Porto Alegre, Brazil

José Carlos Felicetti
Thoracic Surgeon of the Lung
Transplant Group at the Santa Casa
Hospital Complex in Porto Alegre,
Porto Alegre, Brazil

Spencer Marcantonio Camargo
Thoracic Surgeon of the Lung
Transplant Group at the Santa Casa
Hospital Complex in Porto Alegre,
Porto Alegre, Brazil

Fabiola Adélia Perin
Thoracic Surgeon of the Lung
Transplant Group at the Santa Casa
Hospital Complex in Porto Alegre,
Porto Alegre, Brazil

Letícia Beatriz Sanchez
Pulmonologist of the Lung Transplant
Group at the Santa Casa Hospital
Complex in Porto Alegre,
Porto Alegre, Brazil

Sadi Marcelo Schio
Clinical Coordinator for the Lung
Transplant Group at the Santa Casa
Hospital Complex in Porto Alegre,
Porto Alegre, Brazil

References

1. Athanazio RA, Rached SZ, Rohde C, Pinto RC, Fernandes FL, Stelmach R. Should the bronchiectasis treatment given to cystic fibrosis patients be extrapolated to those with bronchiectasis from other causes? *J Bras Pneumol.* 2010;36(4):425-31. PMID:20835888. <http://dx.doi.org/10.1590/S1806-37132010000400006>
2. Ortega HA, Vega Nde A, Santos BQ, Maia GT. Primary ciliary dyskinesia: considerations regarding six cases of Kartagener syndrome. *J Bras Pneumol.* 2007;33(5):602-8. PMID:18026660. <http://dx.doi.org/10.1590/S1806-37132007000500017>
3. Camargo Jde J, Camargo SM, Machuca TN, Perin FA, Schio SM, Felicetti JC. Surgical maneuvers for the management of bronchial complications in lung transplantation. *Eur J Cardiothorac Surg.* 2008;34(6):1206-9. PMID:18715795. <http://dx.doi.org/10.1016/j.ejcts.2008.06.027>
4. Deuse T, Reitz BA. Heart-lung transplantation in situs inversus totalis. *Ann Thorac Surg.* 2009;88(3):1002-3. PMID:19699943. <http://dx.doi.org/10.1016/j.athoracsur.2009.01.060>
5. Miralles A, Muneretto C, Gandjbakhch I, Lecompte Y, Pavie A, Rabago G, et al. Heart-lung transplantation in situs inversus. A case report in a patient with Kartagener's syndrome. *J Thorac Cardiovasc Surg.* 1992;103(2):307-13. PMID:1735997.
6. Rábago G, Copeland JG 3rd, Rosapepe F, Tsen AC, Arzouman DA, Arabia FA, et al. Heart-lung transplantation in situs inversus. *Ann Thorac Surg.* 1996;62(1):296-8. [http://dx.doi.org/10.1016/0003-4975\(96\)00203-2](http://dx.doi.org/10.1016/0003-4975(96)00203-2)
7. Macchiarini P, Chapelier A, Vouhé P, Cerrina J, Ladurie FL, Parquin F, et al. Double lung transplantation in situs inversus with Kartagener's syndrome. Paris-Sud University Lung Transplant Group. *J Thorac Cardiovasc Surg.* 1994;108(1):86-91. PMID:8028384.
8. Lama Martínez R, Santos Luna F, Salvatierra Velázquez A, Cerezo Madueño F, Algar Algar J, Alvarez Kindelán A. Sequential double lung transplant in Kartagener's syndrome [Article in Spanish]. *Arch Bronconeumol.* 2000;36(2):106-8. PMID:10726200.
9. Date H, Yamashita M, Nagahiro I, Aoe M, Andou A, Shimizu N. Living-donor lobar lung transplantation for primary ciliary dyskinesia. *Ann Thorac Surg.* 2001;71(6):2008-9. [http://dx.doi.org/10.1016/S0003-4975\(00\)02276-1](http://dx.doi.org/10.1016/S0003-4975(00)02276-1)